

Neurology of COVID-19

Editor Alberto Priori

DOI: <https://doi.org/10.54103/milanoup.57>

Published by: Milano University Press
Via Festa del Perdono 7 - 20122 Milano
URL: <https://milanoup.unimi.it/>
E-mail: redazione.milanoup@unimi.it

Chapter 13. Disorders of cranial and spinal nerves

DOI: <https://doi.org/10.54103/milanoup.57.25>

List of Contributors

Tommaso Bocci

“Aldo Ravelli” Research Center for Neurotechnology and Experimental Brain Therapeutics, Department of Health Sciences, University of Milan, Milan, Italy;
Neurology Unit I, San Paolo University Hospital, ASST Santi Paolo e Carlo, Milan, Italy.
Email: tommaso.bocci@unimi.it

Laura Campiglio

Neurology Unit I, San Paolo University Hospital, ASST Santi Paolo e Carlo, Milan, Italy.
Email: laura.campiglio@asst-santipaolocarlo.it

Alberto Priori

Professor of Neurology
Director of “Aldo Ravelli” Research Center for Neurotechnology and Experimental Brain Therapeutics, Department of Health Sciences, University of Milan, Milan, Italy;
Director of Neurology Unit I, San Paolo University Hospital, ASST Santi Paolo e Carlo, Milan, Italy.
Email: alberto.priori@unimi.it

Chapter 13. Disorders of cranial and spinal nerves

Tommaso Bocci*, Laura Campiglio*, Alberto Priori

*These authors equally contributed to this work

Non-length dependent neuropathies: Guillain-Barré-Strohl syndrome and COVID-19

Definition and epidemiology

Guillain-Barré-Strohl syndrome (GBS) is an acute, parainfectious autoimmune disease, either axonal or demyelinating, with rapid onset of 3-4 weeks following the primary infection. GBS has been described from the beginning of the COVID-19 pandemic and a number of typical features, both clinical and neurophysiological, have been reported¹⁻³. GBS was reported in 0.1-0.4% of hospitalized patients,⁴⁻⁶ and GBS and variants represent about 21% of the neurological case reports⁷. In general, the mean age, gender and COVID-19 features appear to reflect those of hospitalized COVID patients, while the disease course is more severe than non-COVID-related GBS^{8,9}. The causal relationship between GBS and COVID-19 may be classified as possible or probable. In particular, a probable association is defined when: 1) the disease onset is within 6 weeks of acute infection; 2) either SARS-CoV-2 RNA is detected in any sample or there is antibody evidence of acute SARS-CoV-2 infection; and 3) there is no evidence of other commonly associated causes¹⁰.

Clinical, biochemical and neurophysiological features

Overall, onset of COVID-related GBS seems to follow quickly from the primary infection, as compared to other parainfectious diseases, with neurological signs emerging just one week after respiratory failure. Moreover, in COVID patients, polyradiculoneuropathies primarily affect cranial nerves and are commonly related to an early and severe autonomic dysfunction¹¹⁻¹⁴. In the first reports, axonal GBS was observed, including both acute motor axonal neuropathies (AMAN) and acute motor-sensory axonal neuropathies (AMSAN¹¹). As the pandemic progressed on a global scale, there have also been increasing reports of demyelinating GBS, and the current percentages of axonal and

demyelinating forms are similar^{3,8}. Nonetheless, axonal neuropathies are still more frequent when compared to other parainfectious GBS⁹. The immunological bases are not yet fully understood, and neither are the antibodies involved in the pathophysiology of the disease. However, as likely occurs for the Central Nervous System (CNS), we cannot rule out the possibility of a direct viral invasion of the peripheral nerves and myelin; this could explain the short delay between respiratory symptoms and the early development of neurological signs. As reported in some studies^{2,11}, a direct mechanism may also be suggested by the absence of serum anti-ganglioside antibodies, commonly engaged in the pathophysiology of immune-related disorders.

Putative pathophysiological mechanisms and comparison with other coronaviruses

As described above, the immuno-mediated nature of COVID-related GBS is still a subject of debate and we cannot exclude the possibility of a direct viral invasion. In this scenario, it is worth remembering that the receptor of the angiotensin-conversion enzyme (ACE), the main gate of entry of SARS-CoV-2 into the cells, is highly expressed not only on the neuronal and vascular endothelial surface, but also by Schwann's cells and central oligodendrocytes¹⁵⁻¹⁷. Moreover, to further support the concept of direct viral damage, a prion-like mechanism of neuroinvasion, both at a central and a peripheral level, has been extensively described for other coronaviruses, both in animals and humans¹⁸⁻²¹. These data also fit our recent combined neurophysiological and histopathological findings in severe COVID-19 showing an early involvement of the vagus nerve and respiratory nuclei, probably also accounting for the respiratory failure itself^{22,23}. However, despite the particular abovementioned features of COVID-related GBS, whether COVID patients exhibit an increased risk is still under debate. Recent data suggest that the incidence of GBS in COVID is similar to that described following other infectious diseases^{24,25}, while a larger multi-center study reports a 2.6 fold increased incidence of GBS in Italy during the first pandemic outbreak²⁶. However, the risk of GBS in severe COVID-19 seems to be lower when compared to other emerging infections, such as Zika²⁷.

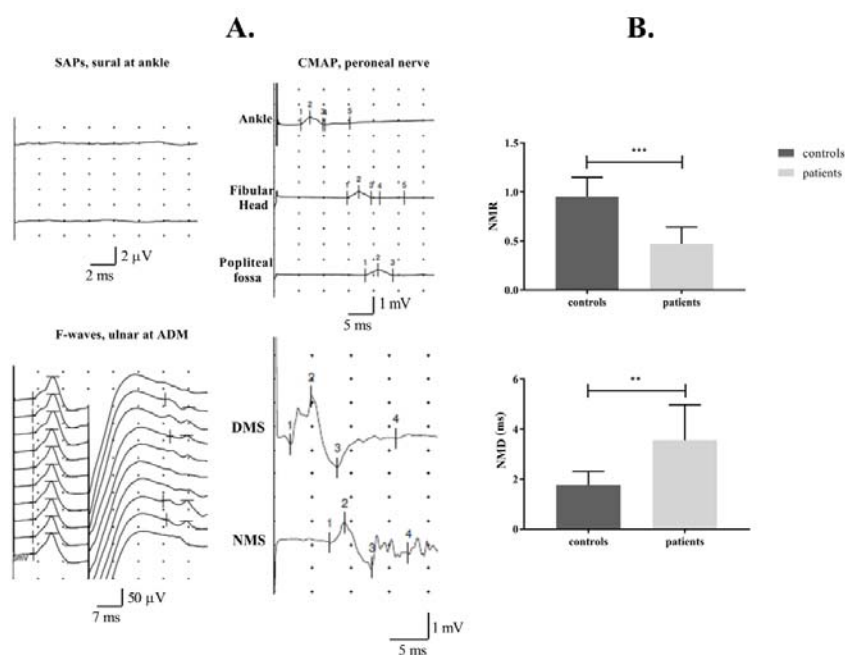
Length-dependent neuropathies

Among other diseases affecting the Peripheral Nervous System, an increasing body of literature has described "Critical Illness Polyneuropathies or Myopathies" (CIP/CIM) in COVID patients, during their stay in the Intensive Care Unit (ICU)²⁸⁻³². The main clinical features are difficulty in weaning the patient off the ventilator and flaccid weakness, thus resulting in areflexic quadriplegia³³⁻³⁶. Although pathophysiologic mechanisms still remain to be established, CIP/CIM usually follows a prolonged treatment of sepsis and may represent the neural manifestation of

multiple organ failure (MOF). Among other causes, high and prolonged doses of corticosteroids and/or non-depolarizing neuromuscular blockers are thought to be strongly associated with these neuromuscular abnormalities³⁴. In non-COVID patients, signs of both neuropathy and myopathy are common, but the myopathic involvement seems to be more frequent and associated to a better clinical outcome^{36,37}.

In comparison with non-COVID patients, a higher percentage of CIP has been described in severe COVID-19^{31,32,38}. This is of key importance given that CIP/CIM may have a different impact on the choice of strategies to be adopted for functional recovery and rehabilitation, possibly delaying ICU discharge for patients affected by predominant neuropathies³⁹. Critical illness neuropathies are probably related to the COVID-induced MOF, but other causes should be taken into consideration, including a possible vasculitic involvement of the *vasa nervorum* and a direct viral invasion of the peripheral nerves by SARS-CoV-2³⁹.

Figure 13.1: Neurophysiological features



The figure shows nerve conduction studies from a representative COVID-19 patient with critical illness neuropathy (CIP). Top: sensory action potentials (SAPs) from the right sural nerve (not recordable) and CMAP (reduced amplitude) derived from the right extensor digitorum brevis; at the bottom (left) F-waves from the left ulnar nerve are provided (with reduced amplitude and impaired representation). Bottom: (right), CMAPs obtained by either Direct Muscle Stimulation (DMS, top trace) or Nerve Motor Stimulation (NMS, bottom) are shown: the significant amplitude reduction, when NMS was compared to DMS, further confirms the predominance of a neuropathic rather than a myopathic pattern (modified from Bocci et al.³⁹, Fig. 1 p. 4).

Although sometimes limited by the very small sample size, studies in COVID-19 have shown that patients with high serum levels of Interleukin-6 (IL-6) and creatin-phosphokinase (CPK) are at the highest risk of developing both muscular and neuropathic impairment^{31,40}. CPK itself is known to represent an independent factor associated with an overall worse clinical outcome and to the development of neurological complications, both at a central and a peripheral level⁴⁰.

Isolated involvement of the cranial nerves

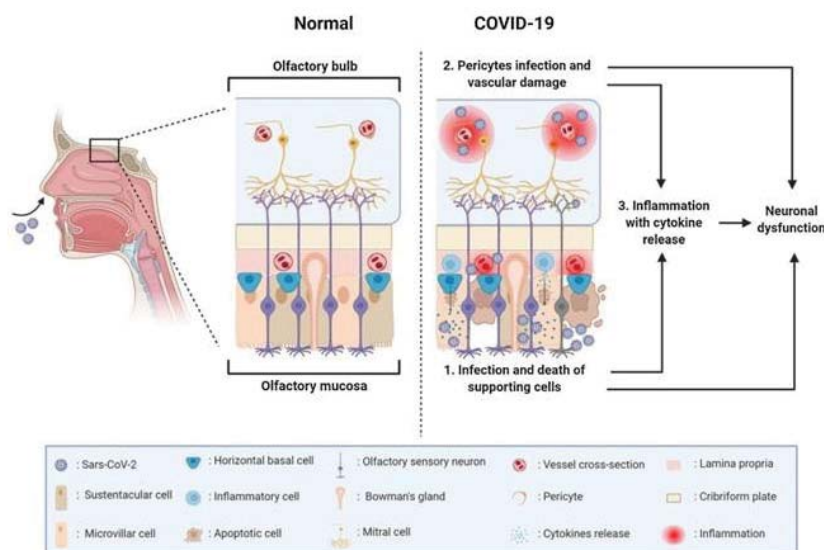
Since the beginning of the pandemic, authors around the world have reported COVID-associated cranial neuropathies, detected by clinical, radiological and neuropathological investigation⁴¹⁻⁴³. In most cases, isolated cranial nerve involvement consisted of hyposmia and dysgeusia, but multiple polyneuritis cranialis or cranial nerves deficits in the context of Miller Fisher Syndrome (MFS) have been observed in a significant number of patients^{13,44}.

Smell and taste disorders

Hyposmia and/or hypogeusia are known to be the main symptoms of SARS-CoV-2 infection. Anosmia has been reported in about 5% of hospitalized patients^{4,44,45}, but its prevalence is considerably higher in dedicated studies, with a frequency ranging from 61% to 86%⁴⁶⁻⁴⁹. According to some studies, anosmia is the first symptom in about 25% of patients⁵⁰ and is nearly always associated with ageusia. These symptoms tend to have an unexpected onset^{51,52} and, because they are often not accompanied by other symptoms, these deficits could be the only indication of infection in otherwise asymptomatic COVID-19⁵³. Most patients report an improvement within the first week, but it is still not known whether some deficit could be permanent⁵². Some Authors propose that the persistence of anosmia is related to lasting SARS-CoV-2 in the olfactory mucosa, while others suggest a central mechanism^{50,54}.

The exact pathogenesis of olfactory dysfunctions is still not fully understood. Animal models have suggested an infection of sensory neurons by SARS-CoV-2 or retrograde brain invasion through the olfactory nerve, but the sudden onset and the fast recovery do not indicate any structural sensory neuron damage and published data are not always in agreement about this^{55,56}. Current evidence suggests an indirect mechanism (infection and inflammation) to non-neural supporting cells of olfactory mucosa, particularly sustentacular and microvillar cells with high expression of ACE2 receptor⁵⁷.

Figure 13.2: Olfactory disorders in SARS-COV-2 infection



1) Local inflammation due to the involvement of supporting cells of the olfactory epithelium. 2) Involvement of endothelial cells and vascular pericytes, leading to hypoperfusion and inflammation. The recruitment of inflammatory cells, cytokine release and generation of neurotoxic compounds modulate the neuronal signaling (from Mastrangelo et al.⁵⁶, Fig. 1 p. 2. Reproduced from ⁵⁶ with permission).

However, the possible occurrence of other mechanisms leading to chemosensory dysfunction and a direct sensory neuron invasion have been postulated^{54,56}. Interestingly, a recent study on post-mortem samples revealed the co-localization of a coronavirus antigen and SARS-CoV-2 RNA in olfactory sensory neurons⁵⁸.

So far, published data on the pathogenesis of taste disorders remain limited. Some studies demonstrated that epithelial cells of the tongue express ACE-2 receptors, hypothesizing a key role for oral mucosa as an entry route for the virus⁵⁹. For the moment there are few data available on the percentage of taste and smell disorders at follow-up. Recent studies seem to suggest that many patients recover quickly, but about 40% of those who experienced smell loss at disease onset may suffer from parosmia during the following six months⁶⁰⁻⁶². This does not depend on the severity of primary infection and is not related to the persistence of other systemic dysfunctions during long-term follow-up.

Optic nerve disorders

Involvement of the optic nerve during COVID-19 is unusual and optic neuritis has rarely been described in patients with SARS-CoV-2 infection^{63,64}. Patients presented with painful vision loss, relative afferent pupillary defect and, in severe cases, visual field defects and optic nerve enhancement on Magnetic Resonance Imaging (MRI)⁶⁴.

In some other COVID-19 patients, optic neuritis was associated with myelin oligodendrocyte glycoprotein (MOG) antibodies. In these cases, SARS-CoV-2

was not detected in the cerebrospinal fluid and researchers postulated that the viral infection triggered the autoimmune response^{65,66}.

Because SARS-CoV-2 is associated with endothelial damage, and thrombotic events are a well described complication of COVID-19, in the case of a sudden visual loss, central retinal artery occlusion and retinal vein occlusion need to be excluded^{67,68}.

Oculomotor nerves

Some cases of oculomotor nerve palsies have been described in patients diagnosed with COVID-19, most often associated with areflexia and ataxia in the context of Miller Fisher Syndrome (MFS)⁶⁹. Case reports on isolated palsy of the III, IV and VI cranial nerves have also been published, and in some of these patients there was no other risk factor for nerve palsy other than SARS-CoV-2 infection⁷⁰. Proposed pathogenetic mechanisms include immune response, ischemia or direct viral involvement of the CNS⁷⁰.

Facial and vestibulocochlear nerves

There has been an increase in the number of reports in the literature of Bell's palsy during SARS-CoV-2 infection but whether these conditions are directly linked or just coincidental is still a matter of debate. While some Authors suggest a higher occurrence of facial palsy during the COVID-19 outbreak, others did not report any significant difference as compared with other infectious disorders⁷¹⁻⁷³.

Although rare, nystagmus, tinnitus and sudden hearing loss have been reported in association with COVID-19⁷⁴.

Lower cranial nerves

Recently, the occurrence of lower cranial neuropathy in post-intubated severe SARS-CoV-2 patients has been reported^{13,75}, with asymmetric involvement of the IX, X, XI and XII cranial nerves leading to dysphagia, hoarseness, weakness of the soft palate, weakness of the trapezius/ sternocleidomastoid and tongue deviation.

Although these alterations have been previously described as the results of traumatic nerve involvement during prolonged intubation (e.g., stretching during lateral head flexion in prone position or nerve compression against the cervical bones), recent neuropathological findings raised the hypothesis of nerve nuclei in the medulla oblongata or a multiple cranial neuropathy. In a post-mortem series, neuroinflammatory changes in the brainstem were the most common findings, with SARS-CoV-2 viral proteins detected in both isolated cells of the brainstem and lower cranial nerves originating from the medulla oblongata²². These data support the hypothesis of an involvement of the brainstem respiratory center in COVID-19 respiratory failure. According to this theory, failure to wean patients

off the ventilator and the respiratory dissociation seen in some patients after recovery from pneumonia could be due to central respiratory drive depression.

Practical recommendations for clinicians and personal experience

During the COVID-19 pandemic, the role and the guidelines for neurophysiological assessment changed rapidly. In particular, safety criteria have been extensively revised in terms of the management and the response of physicians and technicians, hygiene and personal protection standards, and use of technical equipment^{76,77}. At the same time, there has been an increasing need for Telemedicine, not only as a high-specialized “second opinion”.

In our experience, the main limitation was the duration of clinical and electrophysiological assessment for diseases affecting the Peripheral Nervous System. This is because, in COVID, a neurophysiological examination usually takes three times longer than for non-COVID patients, mainly because of safety concerns. Another limitation was the under-estimation of cranial neuropathies, which may frequently complicate the disease course. Moreover, as discussed above, GBS in COVID-19 frequently involves the cranial nerves, even at an early stage, and is more severe than non-COVID-related polyradiculopathies. The cranial nerves are not systematically evaluated in these patients; probably because the attention is usually switched toward the respiratory impairment. Furthermore, the presence of mechanical devices (continuous positive airway pressure or non-invasive ventilation devices) often makes the clinical investigation of cranial nerves very difficult to perform.

Take-home message

- The involvement of the Peripheral Nervous System (PNS) is frequent in severe COVID-19.
- This involvement comprises both length- and non-length dependent diseases, with particular clinical and neurophysiological features when compared to other para-infectious disorders.
- Converging histopathological, clinical and neurophysiological findings suggest that PNS disorders may be due to a direct invasion by SARS-CoV-2.
- PNS involvement can significantly impact the functional recovery and rehabilitation strategies for COVID patients.

References

1. Paterson RW, Brown RL, Benjamin L, et al. The emerging spectrum of COVID-19 neurology: clinical, radiological and laboratory findings. *Brain*. 2020;143(10):3104-3120.
2. Whittaker A, Anson M, Harky A. Neurological Manifestations of COVID-19: A systematic review and current update. *Acta Neurol Scand*. 2020;142(1):14-22.
3. Abu-Rumeileh S, Abdelhak A, Foschi M, et al. Guillain-Barre syndrome spectrum associated with COVID-19: an up-to-date systematic review of 73 cases. *J Neurol*. 2021;268(4):1133-1170.
4. Romero-Sanchez CM, Diaz-Maroto I, Fernandez-Diaz E, et al. Neurologic manifestations in hospitalized patients with COVID-19: The ALBACOVID registry. *Neurology*. 2020;95(8):e1060-e1070.
5. Mahammedi A, Saba L, Vagal A, et al. Imaging of Neurologic Disease in Hospitalized Patients with COVID-19: An Italian Multicenter Retrospective Observational Study. *Radiology*. 2020;297(2):E270-E273.
6. Guilmot A, Maldonado Sloom S, Sellimi A, et al. Immune-mediated neurological syndromes in SARS-CoV-2-infected patients. *J Neurol*. 2021;268(3):751-757.
7. Maury A, Lyoubi A, Peiffer-Smadja N, et al. Neurological manifestations associated with SARS-CoV-2 and other coronaviruses: A narrative review for clinicians. *Rev Neurol (Paris)* 2021;177(1-2):51-64.
8. Filosto M, Cotti Piccinelli S, Gazzina S, et al. Guillain-Barre syndrome and COVID-19: an observational multicentre study from two Italian hotspot regions. *J Neurol Neurosurg Psychiatry*. 2020;92(7):751-756.
9. Caress JB, Castoro RJ, Simmons Z, et al. COVID-19-associated Guillain-Barre syndrome: The early pandemic experience. *Muscle Nerve*. 2020;62(4):485-491.
10. Ellul MA, Benjamin L, Singh B, et al. Neurological associations of COVID-19. *Lancet Neurol*. 2020;19(9):767-783.
11. Toscano G, Palmerini F, Ravaglia S, et al. Guillain-Barre Syndrome Associated with SARS-CoV-2. *N Engl J Med*. 2020;382(26):2574-2576.
12. Gutierrez-Ortiz C, Mendez-Guerrero A, Rodrigo-Rey S, et al. Miller Fisher syndrome and polyneuritis cranialis in COVID-19. *Neurology*. 2020;95(5):e601-e605.
13. Todisco M, Alfonsi E, Arceri S, et al. Isolated bulbar palsy after SARS-CoV-2 infection. *Lancet Neurol*. 2021;20(3):169-170.
14. Zito A, Alfonsi E, Franciotta D, et al. COVID-19 and Guillain-Barre Syndrome: A Case Report and Review of Literature. *Front Neurol*. 2020;11:909.
15. Yang Q, Hughes TA, Kelkar A, et al. Inhibition of SARS-CoV-2 viral entry upon blocking N- and O-glycan elaboration. *Elife*. 2020;9:e61552.
16. Choi JY, Lee HK, Park JH, et al. Altered COVID-19 receptor ACE2 expression in a higher risk group for cerebrovascular disease and ischemic stroke. *Biochem Biophys Res Commun*. 2020;528(3):413-419.
17. Han T, Kang J, Li G, et al. Analysis of 2019-nCoV receptor ACE2 expression in different tissues and its significance study. *Ann Transl Med*. 2020;8(17):1077.

18. Dube M, Le Coupanec A, Wong AHM, et al. Axonal Transport Enables Neuron-to-Neuron Propagation of Human Coronavirus OC43. *J Virol.* 2018;92(17):e00404-18.
19. Li YC, Bai WZ, Hashikawa T. The neuroinvasive potential of SARS-CoV2 may play a role in the respiratory failure of COVID-19 patients. *J Med Virol.* 2020;92(6):552-555.
20. Baig AM, Khaleeq A, Ali U, Syeda H. Evidence of the COVID-19 Virus Targeting the CNS: Tissue Distribution, Host-Virus Interaction, and Proposed Neurotropic Mechanisms. *ACS Chem Neurosci.* 2020;11(7):995-998.
21. Baig AM, Khaleeq A, Nazim F. Targeting CNS Related Protist Pathogens: Calcium Ion Dependency in the Brain-Eating Amoebae. *ACS Chem Neurosci.* 2020;11(16):2385-2387.
22. Bulfamante G, Bocci T, Falleni M, et al. Brainstem neuropathology in two cases of COVID-19: SARS-CoV-2 trafficking between brain and lung. *J Neurol.* 2021. doi:10.1007/s00415-021-10604-8. [Preprint]
23. Bocci T, Bulfamante G, Campiglio L, et al. Brainstem clinical and neurophysiological involvement in COVID-19. *J Neurol.* 2021. doi:10.1007/s00415-021-10474-0. [Preprint]
24. Sejvar JJ, Baughman AL, Wise M, Morgan OW. Population incidence of Guillain-Barre syndrome: a systematic review and meta-analysis. *Neuroepidemiology.* 2011;36(2):123-133.
25. Keddie S, Pakpoor J, Mousele C, et al. Epidemiological and cohort study finds no association between COVID-19 and Guillain-Barre syndrome. *Brain.* 2021;144(2):682-693.
26. Filosto M, Cotti Piccinelli S, Gazzina S, et al. Guillain-Barre syndrome and COVID-19: an observational multicentre study from two Italian hotspot regions. *J Neurol Neurosurg Psychiatry.* 2021;92(7):751-756.
27. Cao-Lormeau VM, Blake A, Mons S, et al. Guillain-Barre Syndrome outbreak associated with Zika virus infection in French Polynesia: a case-control study. *Lancet.* 2016;387(10027):1531-1539.
28. Bagnato S, Boccagni C, Marino G, et al. Critical illness myopathy after COVID-19. *Int J Infect Dis.* 2020;99:276-278.
29. Tankisi H, Tankisi A, Harbo T, et al. Critical illness myopathy as a consequence of Covid-19 infection. *Clin Neurophysiol.* 2020;131(8):1931-1932.
30. Cabanes-Martinez L, Villadoniga M, Gonzalez-Rodriguez L, et al. Clinical and neurophysiological characterization of muscular weakness in severe COVID-19. *Neurol Sci.* 2021;42(6):2173-2178.
31. Bax F, Lettieri C, Marini A, Pellitteri G, Surcinelli A, Valente M, et al. Clinical and neurophysiological characterization of muscular weakness in severe COVID-19. *Neurol Sci.* 2021;42(6):2173-8. doi: 10.1007/s10072-021-05110-8.
32. Frithiof R, Rostami E, Kumlien E, et al. Critical illness polyneuropathy, myopathy and neuronal biomarkers in COVID-19 patients: A prospective study. *Clin Neurophysiol.* 2021;132(7):1733-1740.

33. Bolton CF. Neuromuscular conditions in the intensive care unit. *Intensive Care Med.* 1996;22(9):841-843.
34. De Jonghe B, Cook D, Sharshar T, et al. Acquired neuromuscular disorders in critically ill patients: a systematic review. Groupe de Reflexion et d'Etude sur les Neuromyopathies En Reanimation. *Intensive Care Med.* 1998;24(12):1242-1250.
35. Latronico N, Fenzi F, Recupero D, et al. Critical illness myopathy and neuropathy. *Lancet.* 1996;347(9015):1579-1582.
36. Lefaucheur JP, Nordine T, Rodriguez P, Brochard L. Origin of ICU acquired paresis determined by direct muscle stimulation. *J Neurol Neurosurg Psychiatry.* 2006;77(4):500-506.
37. De Jonghe B, Sharshar T, Lefaucheur JP, et al. Paresis acquired in the intensive care unit: a prospective multicenter study. *JAMA.* 2002;288(22):2859-2867.
38. Tankisi H. Critical illness myopathy and polyneuropathy in Covid-19: Is it a distinct entity? *Clin Neurophysiol.* 2021;132(7):1716-1717.
39. Bocci T, Campiglio L, Zardoni M, et al. Critical Illness Neuropathy in severe COVID-19: a case series. *Neurol Sci.* 2021; <https://doi.org/10.1007/s10072-021-05471-0>.
40. De Rosa A, Verrengia EP, Merlo I, et al. Muscle manifestations and CK levels in COVID infection: results of a large cohort of patients inside a Pandemic COVID-19 Area. *Acta Myol.* 2021;40(1):1-7.
41. Matschke J, Lutgehetmann M, Hagel C, et al. Neuropathology of patients with COVID-19 in Germany: a post-mortem case series. *Lancet Neurol.* 2020;19(11):919-929.
42. Doblan A, Kaplama ME, Ak S, et al. Cranial nerve involvement in COVID-19. *Am J Otolaryngol.* 2021;42(5):102999.
43. Correa DG, Hygino da Cruz LC Jr, Lopes FCR, et al. Magnetic resonance imaging features of COVID-19-related cranial nerve lesions. *J Neurovirol.* 2021;27(1):171-177.
44. Mao L, Jin H, Wang M, et al. Neurologic Manifestations of Hospitalized Patients With Coronavirus Disease 2019 in Wuhan, China. *JAMA Neurol.* 2020;77(6):683-690.
45. Agarwal P, Ray S, Madan A, Tyson B. Neurological manifestations in 404 COVID-19 patients in Washington State. *J Neurol.* 2021;268(3):770-772.
46. Speth MM, Singer-Cornelius T, Oberle M, et al. Olfactory Dysfunction and Sinonasal Symptomatology in COVID-19: Prevalence, Severity, Timing, and Associated Characteristics. *Otolaryngol Head Neck Surg.* 2020;163(1):114-120.
47. Giacomelli A, Pezzati L, Conti F, et al. Self-reported Olfactory and Taste Disorders in Patients With Severe Acute Respiratory Coronavirus 2 Infection: A Cross-sectional Study. *Clin Infect Dis.* 2020;71(15):889-890.
48. Lechien JR, Chiesa-Estomba CM, De Sati DR, et al. Olfactory and gustatory dysfunctions as a clinical presentation of mild-to-moderate forms of the coronavirus disease (COVID-19): a multicenter European study. *Eur Arch Otorhinolaryngol.* 2020;277(8):2251-2261.

49. Sedaghat AR, Gengler I, Speth MM. Olfactory Dysfunction: A Highly Prevalent Symptom of COVID-19 With Public Health Significance. *Otolaryngol Head Neck Surg.* 2020;163(1):12-15.
50. Lorenzo Villalba N, Maouche Y, Alonso Ortiz MB, et al. Anosmia and Dysgeusia in the Absence of Other Respiratory Diseases: Should COVID-19 Infection Be Considered? *Eur J Case Rep Intern Med.* 2020;7(4):001641.
51. Russell B, Moss C, Rigg A, et al. Anosmia and ageusia are emerging as symptoms in patients with COVID-19: What does the current evidence say? *Ecancermedical-science.* 2020;14:ed98.
52. Wu Y, Xu X, Chen Z, et al. Nervous system involvement after infection with COVID-19 and other coronaviruses. *Brain Behav Immun.* 2020;87:18-22.
53. Kaye R, Chang CWD, Kazahaya K, et al. COVID-19 Anosmia Reporting Tool: Initial Findings. *Otolaryngol Head Neck Surg.* 2020;163(1):132-134.
54. Saussez S, Lechien JR, Hopkins C. Anosmia: an evolution of our understanding of its importance in COVID-19 and what questions remain to be answered. *Eur Arch Otorhinolaryngol.* 2021;278(7):2187-2191.
55. Butowt R, von Bartheld CS. Anosmia in COVID-19: Underlying Mechanisms and Assessment of an Olfactory Route to Brain Infection. *Neuroscientist.* 2020. doi: 10.1177/1073858420956905. [Preprint]
56. Mastrangelo A, Bonato M, Cinque P. Smell and taste disorders in COVID-19: From pathogenesis to clinical features and outcomes. *Neurosci Lett.* 2021. doi: 10.1016/j.neulet.2021.135694. [Preprint]
57. Chen M, Shen W, Rowan NR, et al. Elevated ACE-2 expression in the olfactory neuroepithelium: implications for anosmia and upper respiratory SARS-CoV-2 entry and replication. *Eur Respir J.* 2020;56(3):2001948.
58. Meinhardt J, Radke J, Dittmayer C, et al. Olfactory transmucosal SARS-CoV-2 invasion as a port of central nervous system entry in individuals with COVID-19. *Nat Neurosci.* 2021;24(2):168-175.
59. Xu H, Zhong L, Deng J, et al. High expression of ACE2 receptor of 2019-nCoV on the epithelial cells of oral mucosa. *Int J Oral Sci.* 2020;12(1):8.
60. Cook E, Kelly CE, Burges Watson DL, Hopkins C. Parosmia is prevalent and persistent amongst those with COVID-19 olfactory dysfunction. *Rhinology.* 2021;59(2):222-224.
61. Hopkins C, Surda P, Vaira LA, et al. Six month follow-up of self-reported loss of smell during the COVID-19 pandemic. *Rhinology.* 2021;59(1):26-31.
62. Carvalho-Schneider C, Laurent E, Lemaigen A, et al. Follow-up of adults with noncritical COVID-19 two months after symptom onset. *Clin Microbiol Infect.* 2021;27(2):258-263.
63. Benito-Pascual B, Gegundez JA, Diaz-Valle D, et al. Panuveitis and Optic Neuritis as a Possible Initial Presentation of the Novel Coronavirus Disease 2019 (COVID-19). *Ocul Immunol Inflamm.* 2020;28(6):922-925.
64. Rodriguez-Rodriguez MS, Romero-Castro RM, Alvarado-de la Barrera C, et al.

- Optic neuritis following SARS-CoV-2 infection. *J Neurovirol.* 2021;27(2):359-363.
65. Sawalha K, Adeodokun S, Kamoga GR. COVID-19-Induced Acute Bilateral Optic Neuritis. *J Investig Med High Impact Case Rep.* 2020;8:2324709620976018.
66. Zhou S, Jones-Lopez EC, Soneji DJ, et al. Myelin Oligodendrocyte Glycoprotein Antibody-Associated Optic Neuritis and Myelitis in COVID-19. *J Neuroophthalmol.* 2020;40(3):398-402.
67. Murchison AP, Sweid A, Dharia R, et al. Monocular visual loss as the presenting symptom of COVID-19 infection. *Clin Neurol Neurosurg.* 2021;201:106440.
68. Finsterer J, Scorza FA, Scorza CA, Fiorini AC. Vascular Damage May Mimic Retinitis and Optic Neuritis in COVID-19. *Curr Eye Res.* 2021. doi:10.1080/02713683.2021.1896743. [Preprint]
69. Sen M, Honavar SG, Sharma N, Sachdev MS. COVID-19 and Eye: A Review of Ophthalmic Manifestations of COVID-19. *Indian J Ophthalmol.* 2021;69(3):488-509.
70. Anilkumar A, Tan E, Cleaver J, Morrison HD. Isolated abducens nerve palsy in a patient with asymptomatic SARS-CoV-2 infection. *J Clin Neurosci.* 2021;89:65-67.
71. Mutlu A, Kalcioğlu MT, Gunduz AY, et al. Does the SARS-CoV-2 pandemic really increase the frequency of peripheral facial palsy? *Am J Otolaryngol.* 2021;42(5):103032.
72. Islamoglu Y, Celik B, Kiris M. Facial paralysis as the only symptom of COVID-19: A prospective study. *Am J Otolaryngol.* 2021;42(4):102956.
73. Codeluppi L, Venturelli F, Rossi J, et al. Facial palsy during the COVID-19 pandemic. *Brain Behav.* 2021;11(1):e01939.
74. Elibol E. Otolaryngological symptoms in COVID-19. *Eur Arch Otorhinolaryngol.* 2021;278(4):1233-1236.
75. Yatim N, Bonnet N, Wing Tin SN, et al. Persistent bilateral Tapia syndrome following critical COVID-19. *Clin Neurophysiol.* 2021;132(2):505-506.
76. Grippo A, Assenza G, Scarpino M, et al. Electroencephalography during SARS-CoV-2 outbreak: practical recommendations from the task force of the Italian Society of Neurophysiology (SINC), the Italian League Against Epilepsy (LICE), and the Italian Association of Neurophysiology Technologists (AITN). *Neurol Sci.* 2020;41(9):2345-2351.
77. Dubbioso R, Nobile-Orazio E, Manganelli F, et al. Dealing with immune-mediated neuropathies during COVID-19 outbreak: practical recommendations from the task force of the Italian Society of Neurology (SIN), the Italian Society of Clinical Neurophysiology (SINC) and the Italian Peripheral Nervous System Association (ASNP). *Neurol Sci.* 2020;41(6):1345-1348.